

Stents With Torsional Strength for Superficial Femoral Artery Disease: The Prospective Q3-Registry

Journal of Endovascular Therapy
2022, Vol. 29(6) 904–912
© The Author(s) 2022
Article reuse guidelines:
sagepub.com/journals-permissions
DOI: 10.1177/15266028211067726
www.jevt.org
SAGE

Marcus Thieme, MD^{1,2} , Jarwed Arjumand, MD³, Markus Spanagel, MD⁴,
Gunnar Tepe, MD⁵ , Erwin Blessing, MD⁶, Bernd Kroeg, MD⁶,
Viktor Reichert, MD⁷, Stefan Betge, MD⁸ , Ralph Wickenhöfer, MD⁹,
Jörg Teßarek, MD¹⁰, Maja Ingwersen, DVM¹¹, and Hans Krankenberg, MD¹ 

Abstract

Purpose: This postmarketing surveillance study aimed to assess effectiveness and safety of a peripheral self-expanding stent with high torsional strength (POLARIS stent) for the treatment of de novo superficial femoral artery (SFA) lesions in the routine clinical practice.

Materials and Methods: Consecutive patients with symptomatic de novo SFA occlusive disease who underwent POLARIS stent implantation were enrolled into the prospective, multicenter, observational postmarket surveillance study. Primary outcome measure was freedom from clinically driven target lesion revascularization (cdTLR) at 12 months. Main secondary outcomes were procedural success, primary clinical improvement, and freedom from major adverse cardiovascular and limb events (MACLE) throughout 24 months.

Results: A total of 199 participants (70 ± 11 years, 70.4% men) were included in the study at 9 German sites from December 2014 to August 2018. Half of them (52.6%) were current smokers, 37.6% had diabetes, and 25.0% were obese. Most participants suffered from intermittent claudication (88.4%). Mean lesion length was 98 ± 83 mm, 43.5% of lesions were occluded, and 27.3% were severely calcified. Freedom from 12 months cdTLR was 94.4% (95% confidence interval [CI], 90.6–98.2). At 24 months, freedom from cdTLR was 88.7% (95% CI, 83.0–94.4). Procedural success was achieved in 96.2% of participants. Primary clinical improvement occurred in 87.5% and 85.4% of participants at 12 and 24 months, respectively. Freedom from MACLE was 94.8% (95% CI, 91.4–98.1) and 93.8% (95% CI, 89.9–97.6) at 12 and 24 months, respectively.

Conclusions: Treatment of SFA occlusive disease in a real-world setting using the POLARIS stent with high bidirectional torsional strength is efficacious and does not raise any safety concern in the medium term. The study is registered with ClinicalTrials.gov (Identifier: NCT02307292).

Keywords

calcification, chronic total occlusion, endovascular procedures, intermittent claudication, peripheral artery disease, stenosis, stents, superficial femoral artery

Introduction

To date, percutaneous transluminal angioplasty with primary bare metal stenting is standard of care for the treatment of symptomatic femoropopliteal artery disease in patients with intermittent claudication and recommended by current guidelines as such.¹ However, in the last decade, a trend for non-stent interventions, mainly drug-coated balloon (DCB) angioplasty, emerged.² This probably might be attributed to the call of “leaving nothing behind” based on concern about in-stent restenosis, stent thrombosis, and stent fractures. Both bare nitinol stents (BMS) and DCB proved to be superior to plain old balloon angioplasty

(POBA),^{3–8} but, although indirect comparison revealed a similar risk of restenosis and target lesion revascularization (TLR),³ until now, no randomized trial is provided to substantiate noninferiority of DCB against BMS. Moreover, long-term safety of paclitaxel-coated devices is highly controversial.^{9–11}

The ongoing US multicenter XLPAD registry identified superficial femoral artery (SFA) lesion location, increasing lesion length, severe calcification, diffuse lesion pattern, and presence of chronic total occlusions (CTO) as predictors for stent implantation. Nevertheless, at 12 months, incidence of TLR did not differ considerably between stent and non-stent interventions (15% vs 13%, $p=0.23$). Most

stents used were BMS.^{2,12} It may thus be concluded that stent-based interventions are most appropriate for more complex femoropopliteal lesions. A patient-level meta-analysis on BMS in patients with intermittent claudication reported on a 12 month TLR incidence of 9% to 20% depending on lesion length and ankle brachial index (ABI).¹³ Studies on more sophisticated stents such as interwoven BMS and polymer-free or polymer-coated drug-eluting stents (DES) found 12 month TLR incidences of 11%, 8.4%, and 4.5%, respectively.^{14–16}

Due to mechanical forces acting particularly on the femoropopliteal artery segment, stents need to resist torsion, bending, and axial compression during limb flexion. In turn, radial outward force of stents should withstand calcification and high-grade stenosis, however should not compromise the vessel wall. Therefore, specially adapted stent design is decisive for favorable limb outcomes.

To provide reassurance to interventionists, particularly in the light of the tendency to dispense stent implantation in the femoropopliteal segment, we aimed to assess midterm effectiveness and safety of the POLARIS stent (QualiMed, Winsen, Germany), which is characterized by its bidirectional torsional strength and high conformance to physiological vessel rotation, for the treatment of SFA lesions in everyday clinical practice.

Material and Methods

Study Population and Setting

The Q3-registry was a prospective, multicenter, single arm, observational, postmarket surveillance study. Patient's written informed consent to study participation was precondition for enrollment. Clinical follow-up examinations were scheduled at 1, 6, 12, and 24 months (Figure 1). Duplex ultrasound (DUS) examination was at investigators discretion. It was conducted in 39.6%, 42.7%, 27.1%, and 21.1% of participants at 1, 6, 12, and 24 months, respectively. Our study was approved by the Hannover Medical School ethics committee, Hannover, Germany, and by the responsible ethics committees of all investigational sites. It complies

with the Declaration of Helsinki and is registered with ClinicalTrials.gov (Identifier: NCT02307292).

Consecutive patients with a single de novo SFA stenosis (diameter stenosis [DS] >50% by visual estimate) or occlusion with at least one patent outflow artery to the ankle were eligible for enrollment if they were at least 18 years old and assigned to Rutherford category 2 to 4. Enrollment after successful treatment of inflow or outflow lesions within the same interventional session was permitted. Exclusion criteria were pregnancy, acute or subacute thrombosis, hypercoagulopathy, renal failure (creatinine >2.4 mg/dL), impossibility to cross the lesion with a guide wire, and concomitant use of nonstudy stents.

Study Device and Intervention

After successful guidewire passage, lesions were revascularized using the peripheral vascular self-expanding stent system (POLARIS, QualiMed, Winsen, Germany). In 2011, the stent system had achieved CE (conformité européenne) marking for distribution in Europe. Briefly, the self-expanding, bare metal POLARIS stent is made of laser-cut nitinol. It consists of flexible connected wave-like struts to provide both flexibility and radial strength. The stent is available in length up to 200 mm. Peculiarity resides the fact that the stent allows for one full turn (360 degrees) of torsion in both directions without constriction and collapse, referred to as "bidirectional torsional strength." Torsional strength and conformance to normal vessel rotation are supposed to defend against biomechanical forces in the femoral artery segment to preserve patency. In addition, the stent design is intended to prevent marked foreshortening during release. Eight tantalum markers provide visibility under fluoroscopy. Access to the target lesion, predilation, and posttreatment was left to investigators' discretion. Any additional lesion preparation was not permitted. Study medication including anticoagulation and antithrombotic therapy should have been in conformity with current guidelines and hospitals' standard of care.¹ Dual antiplatelet therapy (DAPT) was recommended for at least 4 weeks.

¹Department of Angiology, Cardiology, Diabetology, Regiomed-Vascular Center, Sonneberg, Germany

²Department of Internal Medicine I, Friedrich-Schiller-University, Jena University Hospital, Jena, Germany

³Department of Angiology and Interventional Vascular Medicine, Agaplesion Bethesda Hospital Wuppertal, Wuppertal, Germany

⁴Department of Radiology and Nuclear Medicine, Klinikum Oberberg-Kreis Krankenhaus Waldbröl, Waldbröl, Germany

⁵Department of Diagnostic and Interventional Radiology, Academic Hospital RoMed Clinic of Rosenheim, Rosenheim, Germany

⁶Department of Internal Medicine, SRH Klinikum Karlsbad-Langensteinbach, Karlsbad, Germany

⁷Department of Vascular and Endovascular Surgery, Klinikum Sindelfingen-Böblingen, Sindelfingen, Germany

⁸Department of Internal Medicine and Radiology, Helios Klinikum Salzgitter, Salzgitter, Germany

⁹Department of Radiology, Interventional Radiology and Nuclear Medicine, Herz-Jesu Krankenhaus, Dernbach, Germany

¹⁰Department of Vascular Surgery, Bonifatius Hospital Lingen, Lingen, Germany

¹¹Department of Radiology, Friedrich-Schiller-University, Jena University Hospital, Jena, Germany

Corresponding Author:

Hans Krankenberg, Department of Angiology, Cardiology, Diabetology, Regiomed-Vascular Center, Neustadter Straße 61, Sonneberg 96515, Germany. Email: hans.krankenberg@web.de

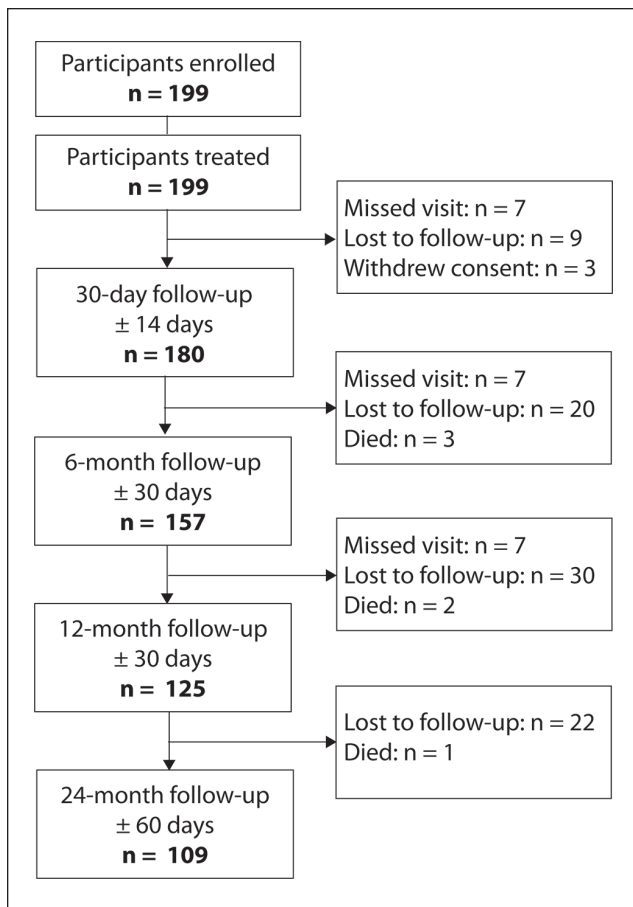


Figure 1. Participant flow.

Study Outcomes

Primary endpoint was freedom from clinically driven target lesion revascularization (cdTLR) at 12 months defined as TLR (ie, repeat revascularization, new bypass graft, or thrombectomy/thrombolysis) on grounds of recurrent symptoms of ischemia and target lesion DS >50% by angiography. Secondary effectiveness outcomes were freedom from cdTLR at 6 and 24 months, technical success (ie, successful access and completion of the procedure with $\leq 30\%$ residual DS), procedural success (ie, technical success without flow-limiting dissection or major adverse cardiovascular or limb events [MACLE] before discharge or within 72 h, whichever comes first), primary clinical improvement (ie, improvement by at least one Rutherford category without the need for TLR), absolute and relative walking distance, and primary hemodynamic improvement (ie, improvement in ABI by ≥ 0.15 or to ≥ 0.9 without the need for TLR). Secondary safety outcomes were cumulative incidence of target lesion restenosis (in-stent or directly proximal or distal of the stent) by DUS or angiography that did not require revascularization, periprocedural complications (up to 30 days from the index procedure), and freedom

from MACLE at 6, 12, and 24 months (composite of cardiovascular death, myocardial infarction, cerebrovascular event, major bleeding, and major target limb amputation).

Statistical Analysis

We reported continuous variables as mean \pm standard deviation (SD) and categorical variables as frequencies and percentages. Differences between continuous variables were assessed with Mann-Whitney *U* test and between categorical variables with Chi-squared test. We conducted Kaplan-Meier analysis to estimate freedom from cdTLR and MACLE. Post hoc, we applied the log-rank test to compare survival curves depending on lesion length, ABI, calcification, and total occlusion (CTO). Results are presented as parameter estimates, standard errors, and corresponding 95% confidence intervals (CI). A two-sided value of $p < 0.05$ indicated statistical significance. The *p* values provided for post hoc analyses should be interpreted only as descriptive. We analyzed data by using XLSTAT (Version 2015.6.01.24026, Addinsoft, Paris, France).

Results

A total of 199 participants (70 ± 11 years, 70.4% men) were included in the study and 199 lesions were treated with the POLARIS stent at 9 German sites from December 2014 to August 2018. In all, 1, 6, 12, and 24 month clinical follow-up examinations were completed in 90.5%, 78.9%, 62.8%, and 54.8% of participants, respectively (Figure 1). Most participants (83.8%) had hypertension and dyslipidemia (70.9%), 52.6% were current smokers, 37.6% had diabetics, and 25.0% were obese. The vast majority were treated for claudication of Rutherford categories 2 and 3 (87.9%; Table 1). Mean lesion length was 98 ± 83 mm. Nearly a quarter (23.5%) of lesions were long lesions (≥ 150 mm) and 43.5% were totally occluded. Multifocal or diffuse pattern occurred in 47.7% and severe calcification in 27.3% of lesions (Table 2). DAPT was conducted in 94% (166 of 176) of participants within the first 4 weeks from intervention. Thereafter, most participants continued with intake of acetylsalicylic acid (94%, 92%, and 87% at 6, 12, and 24 months, respectively). Almost three fourth of participants were on statin throughout the study period (72%, 72%, 71%, and 74% at 1, 6, 12, and 24 months, respectively).

Effectiveness Outcomes

The primary outcome of freedom from cdTLR at 12 months was 94.4% (95% CI, 90.6–98.2). At 6 and 24 months, freedom from cdTLR was 98.8% (95% CI, 97.1–100) and 88.7% (95% CI, 83.0–94.4), respectively. Overall, a total of 14 of 109 (12.8%) participants underwent cdTLR throughout 24 months (Figure 2). Post hoc analysis revealed a

Table 1. Patient Baseline Characteristics (N=199).

	Missing data	
Age (years)	0	69.7±10.8
Men	0	140 (70.4)
Diabetes mellitus	2	74 (37.6)
Insulin	0	29 (14.7)
Dyslipidemia	2	139 (70.9)
Hypertension	1	166 (83.8)
Current smoker	24	92 (52.6)
Obesity ^a	11	47 (25.0)
Coronary artery disease	10	60 (31.7)
Previous cerebrovascular accident	7	17 (8.9)
Renal insufficiency ^b	4	23 (11.8)
Dialysis	0	0 (0.0)
Chronic heart failure	15	12 (6.5)
Infra-popliteal artery disease	11	64 (34.0)
History of peripheral revascularization	5	58 (29.9)
Rutherford category	1	
1		1 (0.51)
2		70 (35.4)
3		104 (52.5)
4		10 (5.1)
5		13 (6.6)
Ankle-brachial index	16	0.60±0.24
Walking distance (m)		
Absolute	74	129±84
Relative	54	111±89

Continuous data are presented as means ± standard deviation and categorical data as counts (percentage).

Abbreviations: BMI, body mass index.

^aBMI≥30 kg/m²

^bGlomerular filtration rate≤60 mL/min.

shorter time to cdTLR in participants with long lesions (short or medium-length lesions: 21.4 months [95% CI, 21.2–21.7]; long lesions: 14.9 months [95% CI, 13.1–16.7], log-rank $p<0.001$). In addition, time to cdTLR tended to be shorter in participants with lower ABI (ABI>0.7: 23.6 months [95% CI, 22.1–25.1]; ABI≤0.7: 20.0 months [95% CI, 19.1–20.9], log-rank $p=0.10$; Figure 3). However, no difference was determined depending on calcification or occlusion (non or mild vs moderate or severe calcification: 15.9 months [95% CI, 15.0–16.7] vs 20.4 months [95% CI, 19.7–21.2], log-rank $p=0.84$; stenosis vs CTO: 20.6 months [95% CI, 19.8–21.4] vs 17.4 months [95% CI, 16.5–18.2], log-rank $p=0.59$).

Technical success was achieved in 197 (99.0%) participants. In 2 participants with severely calcified total occlusions of the distal SFA, a residual stenosis of 50% and 100%, respectively, remained. Procedural success was reached in 176 of 183 (96.2%) participants. Seven participants missed procedural success due to lack of technical success, flow-dissection, or major gastric bleeding (Table 3).

Table 2. Lesion and Procedure Characteristics (N=199).

	Missing data	
Lesion length (mm)	3	97.6±83.4
Lesion length ≥150 mm		46 (23.5)
Lesion location		
Prox SFA	5	70 (36.1)
Mid SFA	5	116 (59.8)
Dist SFA	4	130 (66.7)
Target limb	2	
Left		107 (54.3)
Diameter stenosis (%)	6	61.1±13.1
Total occlusion		84 (43.5)
PTA restenosis	0	6 (3.0)
Pattern	8	
Multifocal		50 (26.2)
Diffuse		41 (21.5)
Calcification ^a	1	
Minor		46 (3.2)
Moderate		74 (37.4)
Severe		54 (27.3)
Thrombus	1	13 (6.7)
Ulceration	1	2 (1.0)
Inflow disease ^b	1	37 (18.7)
Number of patent runoff vessels	9	
1		32 (16.8)
2		52 (27.4)
3		106 (55.8)
Access	0	
Ipsilateral		46 (23.1)
Number of stents deployed	0	1.4±0.7
>2		17 (8.5)
Stented length (mm)	0	114.4±82.4
Stent overlap	0	46 (23.1)
Residual diameter stenosis (%)	0	2.4±9.2
>30%		2 (1.0)

Continuous data are presented as means ± standard deviation and categorical data as counts (percentage).

Abbreviations: SFA, superficial femoral artery; PTA, percutaneous transluminal angioplasty.

^aAngiographic evidence of calcification according to investigators' assessment.

^bInflow disease resolved in the same procedure.

Primary clinical improvement by more than one Rutherford category occurred in 92.0%, 87.5%, and 85.4% of participants at the 6, 12, and 24 month follow-up, respectively ($p<0.001$ for the difference from baseline). Absolute walking distance improved from 129±84 to 580±401 m at 24 months ($p<0.001$; Figure 4). Primary hemodynamic improvement was achieved in 76.2%, 68.5%, and 63.7% of participants at the 6, 12, and 24 month follow-up, respectively (Figure 5).

Safety Outcomes

Cumulative incidence of target lesion restenosis not requiring revascularization was 1% (1 of 79 lesions), 8% (7 of 85

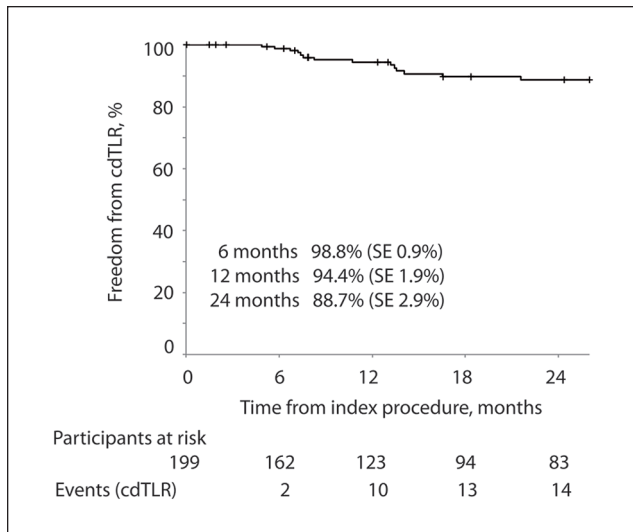


Figure 2. Kaplan-Meier estimate of freedom from target lesion revascularization through 24 months. SE, standard error; cdTLR, clinically driven target lesion revascularization.

lesions), 21% (14 of 68 lesions), and 30% (19 of 64 lesions) during 1, 6, 12, and 24 months, respectively. Periprocedural complications within the first 30 days from index procedure occurred in 16 participants. In 13 of them, these were target lesion dissections (6 of which flow-limiting). Three of the flow-limiting dissections occurred in totally occluded, and 2 in severely calcified lesions. In 1 participant, a nontarget limb false aneurysm was detected. Another 2 participants suffered non-fatal major gastric bleeding at the 1st and 27th day from intervention, respectively. In the latter, a device system component embolized distally (Table 3).

MACLE occurred in 10 of 115 (8.7%) participants throughout 24 months. These consisted of 1 cardiovascular death, 5 cerebrovascular events, 3 myocardial infarctions, 2 major gastric bleedings, and 1 major target limb amputation. One participant died from stroke, and another suffered both stroke and myocardial infarction (Table 4). Freedom from MACLE was 97.8% (95% CI, 95.7–99.9), 94.8% (95% CI, 91.4–98.1), and 93.8% (95% CI, 89.9–97.6) at 6, 12, and 24 months, respectively (Figure 6).

Discussion

We conducted the prospective, multicenter Q3-registry to evaluate effectiveness and safety of the marketed POLARIS stent for the treatment of de novo SFA lesions in daily clinical practice over the medium term. The study stent stands out for high bidirectional torsional strength and conformance to physiological vessel rotation. Our study revealed a favorable incidence of freedom from cdTLR at 12 months which remained high throughout 24 months. Procedural success was achieved in almost all participants, and most of

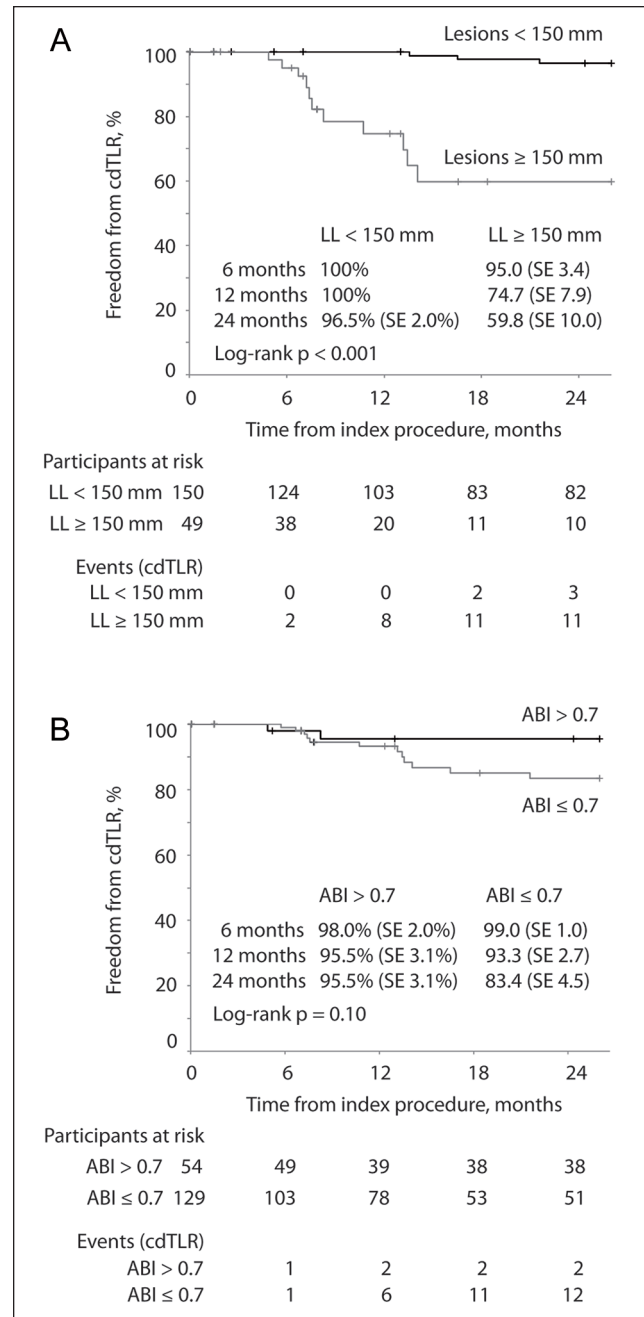


Figure 3. Post hoc comparison of freedom from target lesion revascularization through 24 months depending on lesion length (A) and ABI (B). LL, lesion length; SE, standard error; cdTLR, clinically driven target lesion revascularization; ABI, ankle brachial index.

them presented with sustained clinical improvement at 24 months. MACLE were rare, and investigators assessed none of them as study device related.

With the POLARIS stent, the primary effectiveness outcome of freedom from cdTLR at 12 months was of the same magnitude as reported from previous studies on

Table 3. Acute Procedural Results.

	Missing data	
Technical success ^a	0	197 (99.0)
Procedural success ^b	16	176 (96.2)
Periprocedural complications ^c		
Dissection	152	13 (28)
Flow-limiting dissection		6 (13)
Distal embolization	154	1 (2)
Hematoma	155	0
False aneurysm	25	1 (1.4)
Acute thrombosis	155	0
MACLE ^d at 30 days	16	2 (1.1) ^E

Data are presented as counts (percentage).

Abbreviations: MACLE, major adverse cardiovascular or target limb events.

^aSuccessful access and completion of the procedure with ≤30% residual diameter stenosis.

^bTechnical success without flow-limiting dissection or MACLE before discharge.

^cComplications up to 30 days from index procedure.

^dComposite of cardiovascular death, myocardial infarction, cerebrovascular event, major bleeding, and major target limb amputation.

^ETwo participants experienced major gastrointestinal bleeding at the 1st and 25th day after the procedure, respectively.

contemporary laser-cut BMS (RESILENT RCT: 87.3%; DURABILITY II: 86.1%; 4-EVER: 89.3%; Complete SE: 91.6%; Mimics RCT: 91.0%; and BIOFLEX PEACE: 91.4%).^{6,17–21} Even at 24 months, freedom from TLR was comparable with competitors (Mimics RCT: 91.0%; BIOFLEX PEACE: 85.2%).^{19,21} The ongoing XLPAD registry reported similar limb outcomes with stent compared with non-stent femoropopliteal interventions, however, with a higher share of long, moderate, or severely calcified and occluded lesions in the stented cohort.² This might suggest that there is a strong argument for stent implantation because treatment of complex lesions comes out with similar results as that of less complex lesions.

With interwoven nitinol stents for lesions of 78 mm in length on average and a share of 49% severe vessel calcification, freedom of cdTLR had been achieved in 89% and 84% of participants at 12 and 24 months, respectively.¹⁵ A recent retrospective analysis of data from the XLSTAD registry based on propensity score matching revealed superiority of the interwoven nitinol stent over contemporary laser-cut nitinol stents regarding 12 month TLR (interwoven stents: 7.6%, laser-cut stents: 13.6%, $p=0.04$).²² However, in our study, we found quite similar favorable 12 month results with the laser-cut POLARIS stent as known from the interwoven stent and freedom from cdTLR maintained on a high level up to 24 months. Moderate or severe calcification did not decrease time to cdTLR in both POLARIS and interwoven stent.¹⁵ Moreover, even CTO did

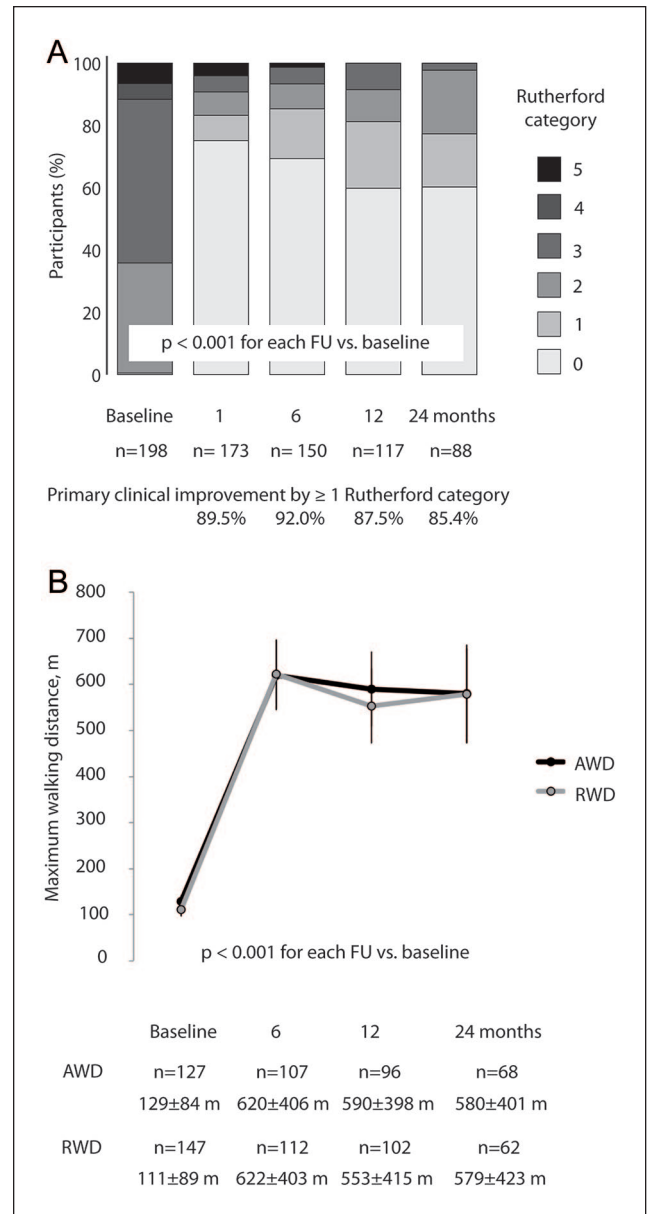


Figure 4. Clinical improvement through 24 months outlined as distribution of Rutherford categories (A) and maximum walking distance (B). Primary clinical improvement reflects percentage of participants who improved clinically by at least one Rutherford category without the need for target lesion revascularization. Values in the line chart are given as means ± standard deviations. Dots represent means with their corresponding 95% confidence interval. AWD, absolute walking distance; FU, follow-up, RWD, relative walking distance.

not affect incidence of cdTLR with the POLARIS stent which suggests sufficient compression resistance against rigid atherosclerotic plaques.

In contrast, severe vessel calcification is an important weakness of DCB compared with stents because circumferential distribution is suspected of impeding drug

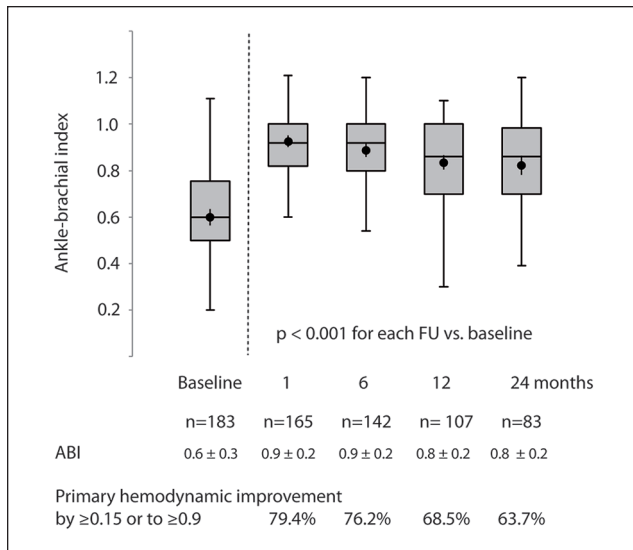


Figure 5. Hemodynamic improvement through 24 months. Primary hemodynamic improvement reflects percentage of participants whose target limb ABI improved by ≥ 0.15 or to ≥ 0.9 without the need for target lesion revascularization. ABI is given in means \pm standard deviations. Box plots indicate median and interquartile range. Whiskers end with the lowest and highest data point within 1.5 times the interquartile range. Dots represent means with their corresponding 95% confidence interval. FU, follow-up; ABI, ankle brachial index.

Table 4. MACLE at 24 Month FU.

	Missing data	
Total MACLE ^a	84	10 (8.7)
Cardiovascular death ^b		1 (0.9)
Myocardial infarction		3 (2.6)
Cerebrovascular event		5 (4.3)
Major bleeding ^c		2 (1.7)
Major target limb amputation		1 (0.9)

Data are presented as counts (percentage). Participants who were lost to follow-up at 24 months were not included in the denominator for calculations of percentages.

Abbreviations: FU, follow-up; MACLE, major adverse cardiovascular or target limb events.

^aComposite of cardiovascular death, myocardial infarction, cerebrovascular event, major bleeding, and major target limb amputation.

^bOne participant died from stroke at 6 months. Another 2 deaths from cancer, 2 from procedure unrelated but not specified reasons, and 1 from unknown reason were not assigned as cardiovascular deaths.

^cTwo participants experienced major gastric bleeding at the 1st and 25th day after the procedure, respectively. The former participant died 16 months after the index procedure for unknown reason.

penetration and preventing formation of drug-reservoirs.^{23,24} Although, in general, DCB proved to be effective with substantial heterogeneity across DCB types, there remains an unexplained safety signal regarding long-term mortality.^{8,11}

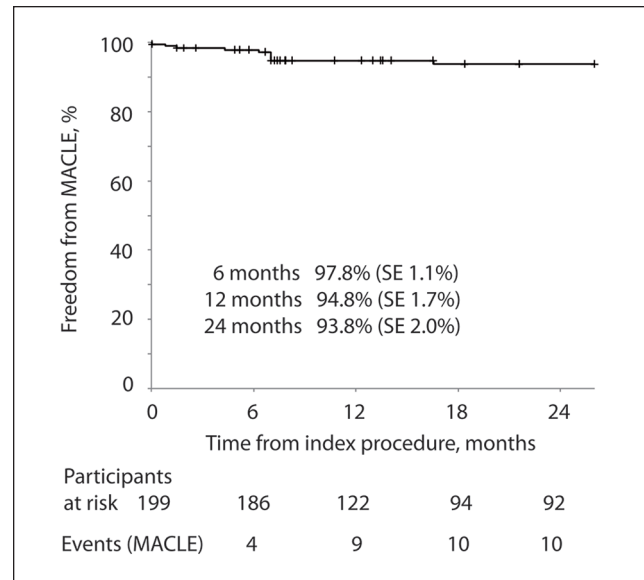


Figure 6. Kaplan-Meier estimate of freedom from major cardiovascular and limb event (composite of cardiovascular death, myocardial infarction, cerebrovascular event, major bleeding, and major target limb amputation). MACLE, cardiovascular and limb event; SE, standard error.

In a retrospective single-center comparison of participants with an average lesion length of 120 mm (severe calcification 39%/40%, critical limb ischemia 27%/29%), polymer-free DES led to comparable results regarding 12 month cdTLR as interwoven nitinol stents (18% vs 13%, p=0.50).²⁵ However, 12 and 24 month freedom from cdTLR with the POLARIS stent was comparable with that reported from polymer-free DES (92% at 12 months and 86% at 24 months; mean lesion length 70 mm, 33% CTOs, 37% severe calcifications)¹⁴ and from polymer-coated DES (95.5% at 12 months and 87.3% at 24 months; mean lesion length 87 mm, 31% CTOs, 40% severe calcifications).^{16,26}

Post hoc comparison of time to cdTLR concerning lesion length in our study gives an indication of less effectiveness of the POLARIS stent in long lesions, which, however, needs further examination.

Unfavorable impact of lesion length on patency was already noted in earlier studies on laser-cut nitinol stents and polymer-free DES.^{13,27-29} It is argued whether stent fractures should be considered as possible cause.³⁰ No direct comparison between laser-cut and interwoven stents for long lesions is provided until now; however, subgroup analysis from the SUPERA 500 registry suggests that with interwoven nitinol stents, lesion length has less unfavorable impact on patency.³⁰ Finally, as deployment of the POLARIS stent is easily manageable, for interwoven nitinol stents, an evenly nominal stent deployment is advisable,¹⁵ which may be difficult to achieve depending on lesion characteristics and investigators' experience.

Study Limitations

Because DUS examination was not mandatory, we did not report primary patency. Instead, we provided restenosis incidence from about 1 in 4 of the study population. Overall, DUS findings might have been affected by selection bias. No core laboratory was involved in angiographic and duplex sonography image evaluation, and no X-ray examination was conducted to document stent integrity. Due to limited power of the post hoc analysis, we cannot provide reasonable assurance whether $ABI \leq 0.7$ can predict cdTLR after nitinol stent implantation as reported earlier.¹³ Finally, clinical improvement and incidence of cdTLR are decisive for assessment of effectiveness and therapy decision. Guideline-recommended statin medication was suboptimal, which might have affected outcomes. In the future, studies with higher sample sizes, longer follow-up period, and randomized comparisons to interwoven nitinol-eluting stents or DES as well as evaluation of combination treatment with DCB are desirable.

Conclusions

The POLARIS stent, which is particularly distinguished by its high bidirectional torsional strength, is efficacious for the treatment of SFA lesions over the medium term, notwithstanding degree of vessel calcification or stenosis. Freedom from major cardiovascular and limb events is favorable. Study results are suitable to reassure interventionists that a stent-based treatment is still appropriate for de novo SFA occlusive disease, particularly in patients with severe vessel calcification or CTO.

Authors' Note

Preliminary results were presented at the Leipzig Interventional Course, Leipzig, Germany, on February 2, 2018, and January 22, 2019.

Declaration of Conflicting Interests

The author(s) declared no potential conflicts of interest with respect to the research, authorship, and/or publication of this article.

Funding

The author(s) disclosed receipt of the following financial support for the research, authorship, and/or publication of this article: The study was funded by an unrestricted grant from QualiMed Innovative Medizinprodukte GmbH, Winsen, Germany. The authors have reported that they have no other relationships relevant to the content of this paper to disclose.

ORCID iDs

Marcus Thieme  <https://orcid.org/0000-0003-1618-0360>

Gunnar Tepe  <https://orcid.org/0000-0002-1239-994X>

Stefan Betge  <https://orcid.org/0000-0002-7251-7389>

Hans Krankenberg  <https://orcid.org/0000-0002-1025-1749>

References

1. Aboyans V, Ricco JB, Bartelink MEL, et al. 2017 ESC guidelines on the diagnosis and treatment of peripheral arterial diseases, in collaboration with the European Society for Vascular Surgery (ESVS): document covering atherosclerotic disease of extracranial carotid and vertebral, mesenteric, renal, upper and lower extremity arteries endorsed by: the European Stroke Organization (ESO) the task force for the diagnosis and treatment of peripheral arterial diseases of the European Society of Cardiology (ESC) and of the European Society for Vascular Surgery (ESVS). *Eur Heart J*. 2018;39:763–816.
2. Banerjee S, Jeon-Slaughter H, Armstrong EJ, et al. Clinical outcomes and cost comparisons of stent and non-stent interventions in infrainguinal peripheral artery disease: insights from the excellence in peripheral artery disease (XLPAD) registry. *J Invasive Cardiol*. 2019;31(1):1–9.
3. Fusaro M, Cassese S, Ndrepepa G, et al. Paclitaxel-coated balloon or primary bare nitinol stent for revascularization of femoropopliteal artery: a meta-analysis of randomized trials versus uncoated balloon and an adjusted indirect comparison. *Int J Cardiol*. 2013;168:4002–4009.
4. Rocha-Singh KJ, Jaff MR, Crabtree TR, et al. Performance goals and endpoint assessments for clinical trials of femoropopliteal bare nitinol stents in patients with symptomatic peripheral arterial disease. *Catheter Cardiovasc Interv*. 2007;69:910–919.
5. Schillinger M, Sabeti S, Loewe C, et al. Balloon angioplasty versus implantation of nitinol stents in the superficial femoral artery. *N Engl J Med*. 2006;354:1879–1888.
6. Laird JR, Katzen BT, Scheinert D, et al. Nitinol stent implantation vs. balloon angioplasty for lesions in the superficial femoral and proximal popliteal arteries of patients with claudication: three-year follow-up from the resilient randomized trial. *J Endovasc Ther*. 2012;19:1–9.
7. Antonopoulos CN, Mylonas SN, Moulakakis KG, et al. A network meta-analysis of randomized controlled trials comparing treatment modalities for de novo superficial femoral artery occlusive lesions. *J Vasc Surg*. 2017;65(1):234–245.
8. Klumb C, Lehmann T, Aschenbach R, et al. Benefit and risk from paclitaxel-coated balloon angioplasty for the treatment of femoropopliteal artery disease: a systematic review and meta-analysis of randomised controlled trials. *Eclinicalmedicine*. 2019;16:42–50.
9. Albrecht T, Schnorr B, Kutschera M, et al. Two-year mortality after angioplasty of the femoro-popliteal artery with uncoated balloons and paclitaxel-coated balloons – a pooled analysis of four randomized controlled multicenter trials. *Cardiovasc Intervent Radiol*. 2019;42(7):949–955.
10. Freisinger E, Koeppel J, Gerss J, et al. Mortality after use of paclitaxel-based devices in peripheral arteries: a real-world safety analysis. *Eur Heart J*. 2020;41:3732–3739.
11. Katsanos K, Spiliopoulos S, Kitrou P, et al. Risk of death following application of paclitaxel-coated balloons and stents in the femoropopliteal artery of the leg: a systematic review and meta-analysis of randomized controlled trials. *J Am Heart Assoc*. 2018;7:e011245.
12. Banerjee S, Pershwitz G, Sarode K, et al. Stent and non-stent based outcomes of infrainguinal peripheral artery interventions from the multicenter XLPAD registry clinical outcomes

- and cost comparisons of stent and non-stent interventions in infrainguinal peripheral artery disease: insights from the excellence in peripheral artery disease (XLPAD) registry. *J Invasive Cardiol.* 2015;27:14–18.
13. Rocha-Singh KJ, Beckman JA, Ansel G, et al. Patient-level meta-analysis of 999 claudicants undergoing primary femoropopliteal nitinol stent implantation. *Catheter Cardiovasc Interv.* 2017;89:1250–1256.
 14. Dake MD, Ansel GM, Jaff MR, et al. Durable clinical effectiveness with paclitaxel-eluting stents in the femoropopliteal artery: 5-year results of the Zilver PTX randomized trial. *Circulation.* 2016;133:1472; discussion 1483–1483.
 15. Garcia LA, Rosenfield KR, Metzger CD, et al. Superb final 3-year outcomes using interwoven nitinol biomimetic supra stent. *Catheter Cardiovasc Interv.* 2017;89:1259–1267.
 16. Gray WA, Keirse K, Soga Y, et al. A polymer-coated, paclitaxel-eluting stent (Eluvia) versus a polymer-free, paclitaxel-coated stent (Zilver PTX) for endovascular femoropopliteal intervention (Imperial): a randomised, non-inferiority trial. *Lancet.* 2018;392:1541–1551.
 17. Bosiers M, Deloose K, Callaert J, et al. 4-French-compatible endovascular material is safe and effective in the treatment of femoropopliteal occlusive disease: results of the 4-EVER trial. *J Endovasc Ther.* 2013;20(6):746–756.
 18. Laird JR, Jain A, Zeller T, et al. Nitinol stent implantation in the superficial femoral artery and proximal popliteal artery: twelve-month results from the complete SE multicenter trial. *J Endovasc Ther.* 2014;21(2):202–212.
 19. Lichtenberg M, Breuckmann F, Kramer V, et al. Effectiveness of the Pulsar-18 self-expanding stent with optional drug-coated balloon angioplasty in the treatment of femoropopliteal lesions – the BIOFLEX Peace All-Comers Registry. *Vasa.* 2019;48(5):425–432.
 20. Matsumura JS, Yamanouchi D, Goldstein JA, et al. The United States study for evaluating endovascular treatments of lesions in the superficial femoral artery and proximal popliteal by using the Protégé Everflex Nitinol Stent System II (DURABILITY II). *J Vasc Surg.* 2013;58(1):73–83.
 21. Zeller T, Gaines PA, Ansel GM, et al. Helical centerline stent improves patency: two-year results from the randomized mimics trial. *Circ Cardiovasc Interv.* 2016;9(6):e002930.
 22. Armstrong EJ, Jeon-Slaughter H, Kahlon RS, et al. Comparative outcomes of supra interwoven nitinol vs bare nitinol stents for the treatment of femoropopliteal disease: insights from the XLPAD registry. *J Endovasc Ther.* 2020;27(1):60–65.
 23. Fanelli F, Cannavale A, Gazzetti M, et al. Calcium burden assessment and impact on drug-eluting balloons in peripheral arterial disease. *Cardiovasc Intervent Radiol.* 2014;37(4):898–907.
 24. Rocha-Singh KJ, Zeller T, Jaff MR. Peripheral arterial calcification: prevalence, mechanism, detection, and clinical implications. *Catheter Cardiovasc Interv.* 2014;83:E212–E220.
 25. Haine A, Schmid MJ, Schindewolf M, et al. Comparison between interwoven nitinol and drug eluting stents for endovascular treatment of femoropopliteal artery disease. *Eur J Vasc Endovasc Surg.* 2019;58(6):865–873.
 26. Müller-Hülsbeck S, Benko A, Soga Y, et al. Two-year efficacy and safety results from the imperial randomized study of the Eluvia polymer-coated drug-eluting stent and the Zilver PTX polymer-free drug-coated stent. *Cardiovasc Intervent Radiol.* 2021;44(3):368–375.
 27. Bosiers M, Deloose K, Callaert J, et al. Results of the Protégé Everflex 200-mm-long nitinol stent (ev3) in TASC C and D femoropopliteal lesions. *J Vasc Surg.* 2011;54(4):1042–1050.
 28. Bosiers M, Peeters P, Tessarek J, et al. The Zilver® PTX® single arm study: 12-month results from the TASC C/D lesion subgroup. *J Cardiovasc Surg (Torino).* 2013;54(1):115–122.
 29. Davaine JM, Azéma L, Guyomarch B, et al. One-year clinical outcome after primary stenting for Trans-Atlantic Inter-Society Consensus (TASC) C and D femoropopliteal lesions (the STELLA “STEnting Long de L’artère fémorale superficielle” cohort). *Eur J Vasc Endovasc Surg.* 2012;44(4):432–441.
 30. Werner M, Paetzold A, Banning-Eichenseer U, et al. Treatment of complex atherosclerotic femoropopliteal artery disease with a self-expanding interwoven nitinol stent: midterm results from the Leipzig SUPERA 500 registry. *Eurointervention.* 2014;10(7):861–868.