

Sehirli, Eftal; Kamil, Turan Muhammed; Dietzel, Alexander

Automatic Detection of Microaneurysms in RGB Retinal Fundus Images

URN: urn:nbn:de:gbv:ilm1-2016200108

Original published in:

International Journal of Scientific and Technological Research. – IISTE, 1 (2015), 8, p. 1-7.

ISSN (online): 2422-8702

URL: <http://www.iiste.org/Journals/index.php/JSTR/article/view/26360>

[Visited: 2016-07-27]

Notes from the publisher's website:

Users are free to read, download, copy, distribute, print, search, or link to the full texts of these articles without requiring a subscription to the journal in which these articles are published.

<http://www.iiste.org/journals-old/open-access-policy-and-ethics/>

Automatic Detection of Microaneurysms in RGB Retinal Fundus Images

Eftal Sehirli (Corresponding author)

Karabuk University, Engineering Faculty, Department of Biomedical Engineering
78050, Karabuk, Turkey, E-mail: eftalsehirli@karabuk.edu.tr

Muhammed Kamil Turan

Karabuk University, Medicine Faculty, Department of Medical Biology
78050, Karabuk, Turkey

Alexander Dietzel

Technische Universitat Ilmenau, Institute of Biomedical Engineering and Computer Science,
Department of Biomedical Engineering 98684, Ilmenau, Germany

Abstract

In this study, an efficient and fast-working method to detect microaneurysm lesions, first symptom of diabetic retinopathy, is described. The proposed method is based on mathematical morphology, object pixel classification and connected component analysis. The proposed algorithm responses in 4.8 seconds for 2048x1536 pixel images. This shows this system runs faster than other microaneurysm detection systems. The sensitivity and specificity of this system is 69.1% and 99.3% specificity, respectively.

Keywords: Connected component analysis, Diabetic retinopathy, Microaneurysm, Mathematical morphology.

1. Introduction

Diabetes mellitus known as diabetes all over the world is a multi-system disease which causes vision loss and may result in cataract. It is due to be unable to regulate blood sugar well [1]. High level blood sugar may damage blood vessels of eye which is called as diabetic retinopathy. Diabetic retinopathy is a progressive eye disease which might result in blindness due to changes like bleeding and vascularization [2, 3].

Diabetic retinopathy contains two stages which are non-proliferative and proliferative diabetic retinopathy. First symptom of diabetic retinopathy falling within non-proliferative stage is microaneurysm. Color of microaneurysm is red and its size changes between 10 and 100 μm [4, 5]. To prevent diabetic patients from vision loss and blindness, microaneurysm detection is necessary.

A number of methods to detect microaneurysm lesions have been proposed in the literature. Mathematical morphology has been used to extract blood vessels from fundus images in Baudoin et al. [6], Kande et al. [7], Spencer et al. [8] and Fleming et al. [9]. After extraction of blood vessels, support vector machine and connected component analysis were used to classify and eliminate candidate red lesions in Kande et al. [7], region-growing algorithm was used to detect microaneurysms in Spencer et al. [8]. Fleming et al. [9] has developed mathematical morphology algorithm by adding local contrast normalization method to eliminate candidates. Streeter and Cree [10] has proposed a top-hat method to suppress vessels and filter by using complex-valued and circular symmetric filters on Eigen images. Morphological analysis has been done to decrease false positive rate. Bhalerao et al. [11] has proposed an algorithm based on median filter and blob detection for preprocessing and circular symmetric filters to differentiate microaneurysm from vessels. Matched filter and morphological analysis has been utilized for candidate regions.

There are some difficulties to detect microaneurysm lesion on RGB retinal fundus images. Red lesions such as blood vessels and hemorrhages on retina have same color with microaneurysm. In addition to this, bright areas such as optic disc and exudates make microaneurysm detection difficult. Consequently, number of false positives and false negatives increase. Our main objective in this study is to develop a software to detect microaneurysm lesions automatically in a short time with a very high specificity and reasonable sensitivity. The performance of the system about specificity and response time is higher than almost other studies. This paper consists of three sections such as Proposed Algorithm, Results and Discussions, Conclusion. In Proposed algorithm section, steps and details of proposed algorithm are presented. In Results and Discussions section, obtained results are shown and compared with other

studies. In Conclusion section, conclusions are presented.

2. Proposed Algorithm

The proposed algorithm is designed as a fully automatic system to detect microaneurysm lesions. Fig 1 shows the block diagram of the system. The system takes RGB retinal images as input and marks the microaneurysm lesions on it, then counts the microaneurysm lesions and returns both of them as outputs. The proposed algorithm consists of three main parts such as pre-processing, feature extraction and classification-elimination.

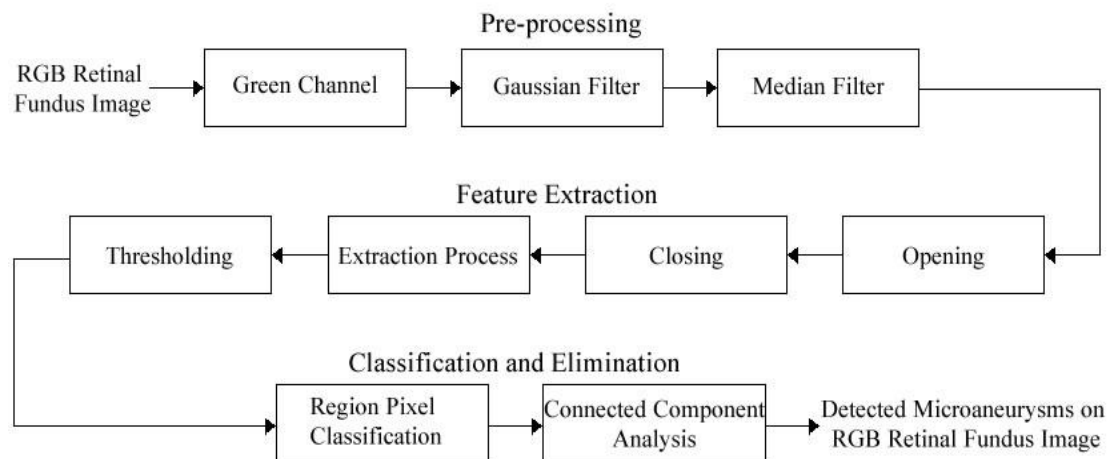


Figure 1. Basic block diagram of the system

2.1. Pre-processing

Pre-processing stage is to work on better images than original images. It is a necessary stage in this study to improve image quality, get rid of noises, and enhance contrast and separate background with objects on the image. First of all, original image shown in Fig. 2a is converted to green channel image shown in Fig. 2b since contrast difference between background and red or almost red objects is higher. In addition to this, green channel image is more explicit than red channel and blue channel images. Gaussian filter and median filter are applied to get rid of noises. For both, a 3x3 window is performed on green channel images. Result images are shown in Fig. 2c and Fig. 2d.

2.2. Feature Extraction

The next step is to apply opening and closing processes to help feature extraction. Opening process is erosion followed by dilation. Erosion is a process which makes objects smaller or thinner, supplies to make holes (if exist) bigger and separates connected components. Dilation is a process which makes objects bigger or thicker, supplies to make holes (if exist) smaller and makes connected components closer to each other [12]. The formula of opening process is shown below.

$$A \circ B = (A \ominus B) \oplus B$$

Opening process is used along with structuring element function. Disc and 8 values were used as parameters of structuring element function. The result image is shown in Fig. 2e after opening process is applied.

Closing process in contrast with opening process is dilation followed by erosion. The formula of closing process is shown below.

$$A \bullet B = (A \oplus B) \ominus B$$

Opening process is used along with structuring element function. Disc and 6 values are used as parameters of structuring element function. The result image is shown in Fig. 2f after closing process is applied. As a result, lost areas and objects are obtained by opening and closing processes. After that, the result image is subtracted from green channel image. Thus, some parts of big areas such as blood vessels, optic disc and exudates are removed. The image obtained by subtraction process is shown in Fig. 2g.

It is necessary to convert the image to a binary image so as to apply threshold method and make operations on connected component objects. Otsu threshold method is applied to have a binary image. Threshold value is automatically determined according to input image. The result image obtained by Otsu threshold method is shown in Fig. 2h.

2.3. Classification and Elimination

Object pixel classification is done on the result image at this step. Because size of microaneurysm lesions is between 10 and 100 μm , firstly objects whose sizes are less than 10 pixels are removed and the result image is called as A. Secondly, objects whose sizes are less than 100 pixels are removed and the result image is called as B. When B image is extracted from A image, the result image has only objects whose sizes are between 10 and 100 pixels. That is, candidate microaneurysms are left on the image shown in Fig. 2i.

Connected component analysis is applied to eliminate candidates from images. Because shape property of microaneurysm lesions are like ellipse, eccentricity property of connected component objects is performed on images. Eccentricity is a property which takes values between 0 and 1. When shape of an object is circle, eccentricity converges to 1. When shape of an object is straight line, eccentricity converges to 0. Eccentricity is the ratio of the distance between foci and axis length of the object. Since microaneurysm lesions are like ellipse objects, in this study eccentricity value is empirically calculated as 0.83 during experiments and used throughout this study. The result image is shown in Fig. 2j.

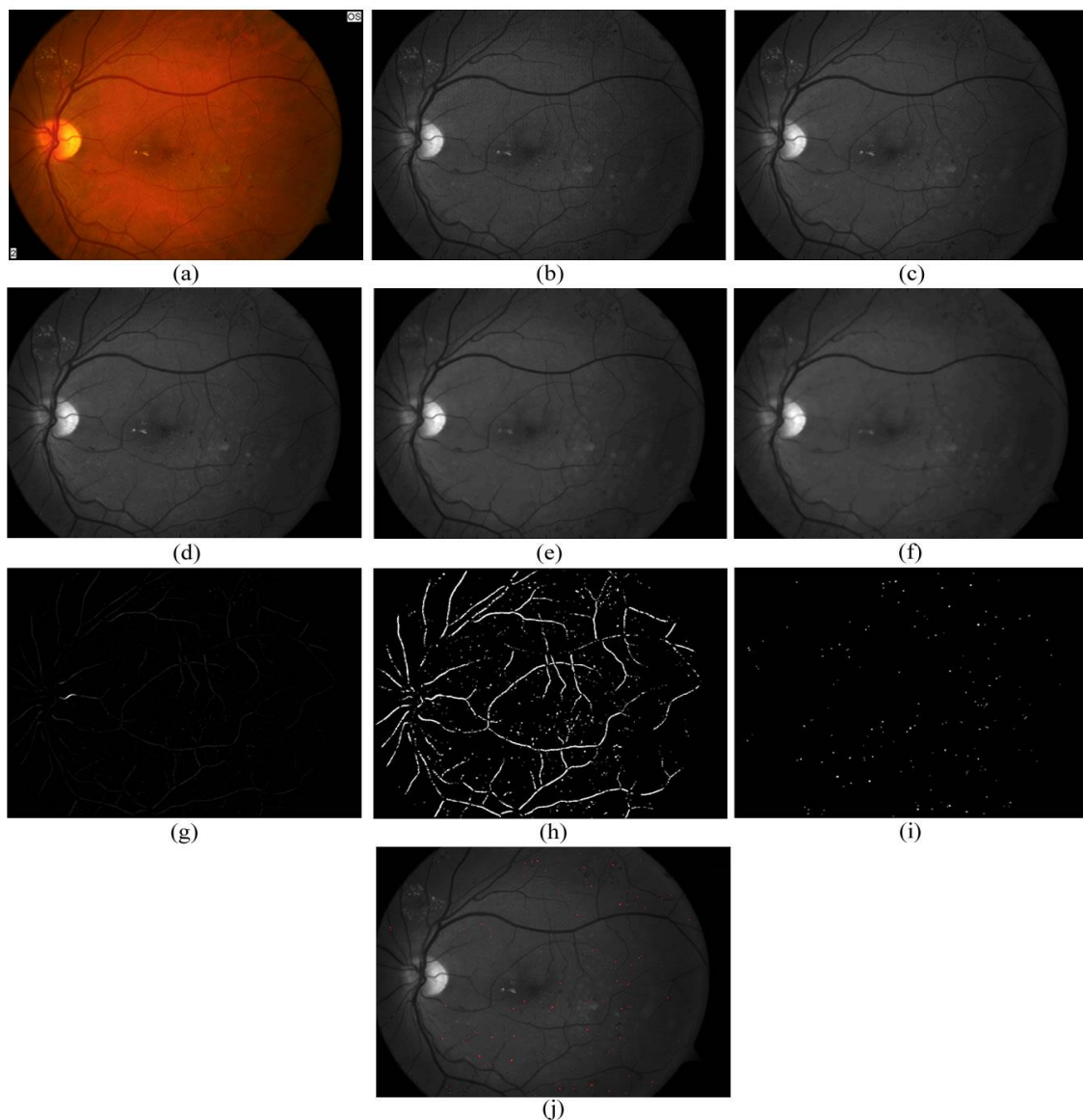


Figure 2. Results of each step

[(a) Original image. (b) Green channel image. (c) Result image after Gaussian filter (3x3 window). (d) Result image after median filter (3x3 window). (e) Result image after opening process. (f) Result image after closing process. (g) Result image after subtraction process. (h) Result image after Otsu thresholding. (i) Candidate microaneurysm lesions. (j) Microaneurysm lesions.]

3. Results and Discussions

One hundred thirteen RGB retinal fundus images were tested by the proposed algorithm in order to detect microaneurysms. Many of images were obtained by retrospective archive of department of eye diseases of Karabük University Medicine Faculty. These images contain microaneurysm lesions and they were captured by a scientific camera. The scientific camera whose features are shown in Table 1 is used to capture RGB retinal fundus images. Some images were taken from Biomedical Engineering Institute of Ilmenau Technische University and they were used for test.

Table 1. Features of the scientific camera

Parameter	Feature
Brand name	Canon
Resolution	22.3 MP
Image size	2048x1536
Sensitivity	ISO 25600

When the proposed algorithm is performed, all steps of the proposed algorithm for a sample RGB retinal fundus image are shown in Fig. 2 for a sample RGB retinal fundus image.

All 2048x1536 pixel images were tested on an i7 4.00 GHz PC using Matlab. The average response time for an image is 4.8 seconds although image resolutions are high.

The accuracy of the proposed algorithm has been evaluated by sensitivity and specificity values. To calculate both of them, four statistical measures such as true positive (TP), false negative (FN), false positive (FP) and true negative (TN) are calculated. TP means a diseased person who is correctly identified as having a disease by the test. FN means a diseased person who is incorrectly identified healthy by the test. FP means a healthy person that is incorrectly identified as having the disease by the test. TN means a healthy person who is correctly identified as healthy by the test.

Table 2. Statistical measures

Test Result – Expert Result	Microaneurysm	Non-microaneurysm
Microaneurysm	TP	FP
Non-microaneurysm	FN	TN

$$\text{Sensitivity} = TP / (TP + FN)$$

$$\text{Specificity} = TN / (TN + FP)$$

It is aimed at reaching 100% for both sensitivity and specificity. However, sensitivity and specificity decrease since images have noises, artefacts, too small microaneurysms and remaining parts after feature extraction. For the proposed algorithm, the average sensitivity and specificity are 69.1% and 99.3%, respectively. A sample image whose microaneurysm lesions are detected is shown in Fig. 3.

Trucco et al. [13] published a paper which shows sensitivity and specificity results of other papers about detection of microaneurysms. The comparison of results with regard to sensitivity and specificity is shown in Table 3 below.

4. Conclusion

In this paper, we have proposed an algorithm to detect microaneurysms in RGB retinal fundus images taken from diabetic retinopathy patients. The proposed method is based on mathematical morphology, object pixel classification and connected component analysis. It performs reasonable sensitivity 69.1% and very high specificity 99.3% for only 2048x1536 pixel images and takes average 4.8 seconds for calculation. Therefore, our microaneurysm detection system is a helpful model and performs better than other studies in the literature about specificity and response time.

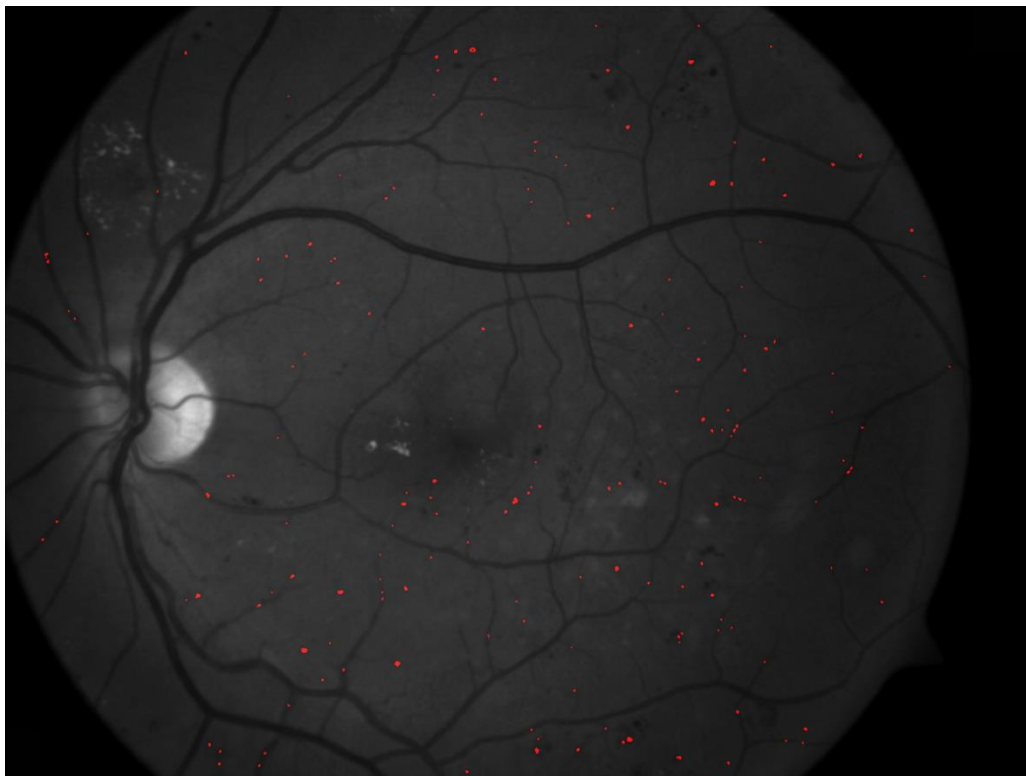

Figure 3. A sample result image

Table 3. The comparison of results with regard to sensitivity and specificity

Author	Sensitivity	Specificity
The proposed algorithm	69.1%	99.3%
SujithKumar et al. [5]	94.44%	87.5%
Baudoin et al. [6]	70%	86%
Kande et al. [7]	100%	91%
Fleming et al. [9]	85.40%	83.10%
Streeter & Cree [10]	56%	5.7 FP
Bhalerao et al. [11]	82.6%	80.2%
Tavakoli et al. [13,14]	94%	75%
Giancardo et al. [13,15]	50%	>10 FP
Niemeijer et al. [13,16]	60%	8 FP
Mizutani et al. [13,17]	65%	27 FP
Quellec et al. [13,18]	90.24%	89.75%
Walter et al. [13,19]	88.50%	2.13 FP
Huang et al. [13,20]	68%	>40 FP
Quellec et al. [13,21]	87.90%	96.20%
Serrano et al. [13,22]	90.72%	82.35%
Yang et al. [13,23]	90%	80%
Hipwell et al. [13,24]	85%	76%
Cree et al. [13,25]	82%	84%
Spencer et al. [13,26]	45%	>150 FP

5. Acknowledgement

Our appreciation to Abdullah Elen and Seyit Ali Kayış who have contributed towards development of the system and the template.

References

- [1] Tierney, L.M., McPhee, S.J., & Papadakis, M.A. (2002). *Current Medical Diagnosis & Treatment*, (International ed.). New York; Lange Medical Books/McGraw-Hill.
- [2] Burda, N., Mema, V., Mahmudi, E., Selimi, B., Zhugli, S., Lenajni, B., & Bunjaku, I. (2013). Prevalence of dry eye syndrome at patients with diabetes melitus TIP 2. *Journal of Acute Disease*, 2, 48-51.
- [3] Akram, M.U., Khalid, S., & Khan, S.A. (2013). Identification and classification of microaneurysms for early detection of diabetic retinopathy. *Pattern Recognition*, 46, 107-116.
- [4] Atmaca, L., & Sönmez, P.A. (2002). Nonproliferatif ve proliferatif diabetik retinopatide ışık koagüleasyonu. *Ret-vit*, 10, 103-112.
- [5] Sujithkumar, S.B., & Vipula, S. (2012). Automatic detection of diabetic retinopathy in non-dilated RGB retinal fundus images. *International Journal of Computer Applications*, 47, 26-32.
- [6] Baudoin, C., Lay B., & Klein, J. (1984). Automatic detection of microaneurysms in diabetic fluorescein angiography. *Revue depidemiologie et de sante publique*, 32, 254-261.
- [7] Kande, G.B., Savithri, T.S. & Subbaiah, P.V. (2010). Automatic detection of microaneurysms and hemorrhages in digital fundus images. *Journal of Digital Imaging*, 23, 430-437.
- [8] Spencer, T., Olson, J., McHardy, K., Sharp P., & Forrester, J. (1996). An image processing strategy for the segmentation and quantification in fluorescein angiograms of the ocular fundus. *Comput Biomed Res*, 29, 284-302.
- [9] Fleming, A.D., Philip, S., Goatman, K.A., Oslon, J.A. & Sharp P.F. (2006). Automated microaneurysms detection using local contrast normalization and local vessel detection. *IEEE Trans Med Image*, 25, 1223-1232.
- [10] Streeter, L., & Cree M.J. (2003). Microaneurysm detection in color fundus images. *Image and Vision Computing NZ*, 280-285.
- [11] Bhalerao, A., Patanaik, A., Anand, S., & Saravanan, P. (2008). Robust detection of microaneurysms for sight threatening retinopathy screening. *6th Indian Conference on Computer Vision, Graphics & Image Processing*, 520-527.
- [12] Karhan, M., Oktay, M.O., Karhan, Z., & Demir, H. (2011). Morfolojik görüntü işleme yöntemleri ile kayıslarda yaprak delen (çil) hastalığı sonucu oluşan lekelerin tespiti. *6th International Advanced Technologies Symposium (IATS'11)*, 172-176.
- [13] Trucco, E., Ruggeri, A., Karnowski, T., Giancardo, L., Chaum, E., Hubschman, J.P., Al-Diri, B., Cheung, C.Y., Wong, D., Abramoff, M., Lim, G., Kumar, D., Burlina, P., Bressler, N.M., Jelinek, H., Meriaudeau, F., Quellec, G., MacGillivray, T., & Dhillon, B. (2013). Validating retinal fundus image analysis algorithms: issues and a proposal. *Inverstigative Ophthalmology and Visual Science*, 54, 3546-3559.
- [14] Tavakoli, M., Shahri, R.P., Pourreza H., Mehdizadeh, A., Banaee, T., & Toosi, M.H.B. (2013). A complementary method for automated detection of microaneurysms in fluorescein angiography fundus images to assess diabetic retinopathy. *Pattern Recognition*, 46, 2740-2753.
- [15] Giancardo, L., Meriaudeau, F., Karnowski, T.P., Li, Y., Tobin, K.W. Jr., & Chaum, E. (2011). Microaneurysm detection with Radon transform based classification on retina images. *Conf Proc IEEE Eng Med Biol Soc*, 5939-5942.
- [16] Niemeijer, M., Ginneken, B., Cree, M.J., et al. (2010). Retinopathy online challenge: automatic detection of microaneurysms in digital color fundus photographs. *IEEE Trans Med Imaging*, 29, 185-195.
- [17] Mizutani, A., Muramatsu, C., Hatanaka, Y., Suemori, S., Hara, T., & Fujita H. (2009). Automated microaneurysm detection method based on double ring filter in retinal fundus images. *Proc SPIE*:

Medical Imaging, 7260, 72601N-1-8.

- [18] Quéllec, G., Lamard, M., Josselin, P.M., Cazuguel, G., Cochener, B., & Roux, C. (2008). Optimal wavelet transform for the detection of microaneurysms in retina photographs. *IEEE Trans Med Imaging*, 27, 1230–1241.
- [19] Walter, T., Massin, P., Erginay, A., Ordonez, R., Jeulin, C., & Klein, J.C. (2007). Automatic detection of microaneurysms in color fundus images. *Med Image Anal*, 11, 555–566.
- [20] Huang, K., Yan, M., & Aviyente, S. (2007). Edge-directed inference for microaneurysms detection in digital fundus images. *SPIE Medical Imaging: Image Processing*, 6512.
- [21] Quéllec, G., Lamard, M., Josselin, P.M., Cazuguel, G., Cochener, B., & Roux, C. (2006). Detection of lesions in retina photographs based on the wavelet transform. *EMBS'06. 28th Annual International Conference of the IEEE*, 1, 2618-2621.
- [22] Serrano, C., Acha, B., & Revuelto, S. (2004). 2D adaptive filtering and region growing algorithm for the detection of microaneurysms. *SPIE Medical Imaging: Image Processing*, 5370, 1924–1931.
- [23] Yang, G., Gagnon, L., Wang, S., & Boucher, M.C. (2001). Algorithm for detecting micro-aneurysms in low-resolution color retinal images. *Vision Interface*, 265–271.
- [24] Hipwell, J.H., Strachan, F., Olson, J.A., et al. (2000). Automated detection of microaneurysms in digital red-free photographs: a diabetic retinopathy screening tool. *Diabetic Med*, 17, 588–594.
- [25] Cree, M.J., Olson, J.A., McHardy, K.C., et al. (1997). A fully automated comparative microaneurysm digital detection system. *Eye*, 11, 622–629.
- [26] Spencer, T., Phillips, R.P., Sharp, P.F., & Forrester, J.V. (1992). Automated detection and quantification of microaneurysms in fluorescein angiograms. *Graefes Arch Clin Exp Ophthalmol.*, 30, 36–41.